

Medical complications in long-term survivors with X-linked myotubular myopathy

Gail E. Herman, MD, PhD, Milton Finegold, MD, Wei Zhao, MS, Beatrice de Gouyon, PhD, and Aida Metzenberg, PhD

Objectives: X-linked myotubular myopathy (MTM1) is a rare developmental disorder of skeletal muscle characterized by the presence of central nuclei in biopsy specimens from affected male subjects. Until recently, the disorder was usually fatal within the first year of life. This study was undertaken to determine the outcome in long-term survivors (>1 year of age) with MTM1.

Methods: Clinical data were obtained on 55 male subjects from 49 independent North American families for which a mutation was identified in the X-linked myotubularin gene by direct genomic sequencing. Medical records were reviewed and families were interviewed to ascertain features at birth, length of survival, developmental milestones, and medical complications.

Results: Seventy-four percent (26 of 35) of the affected male subjects over the age of 1 year are living (range, 1 to 27 years); 80% remain completely or partially ventilator-dependent. In the absence of significant hypoxia, cognitive development is normal, and the muscle disorder appears nonprogressive. Several patients have had other medical problems not previously reported to be associated with MTM1. These include pyloric stenosis (4 male subjects from 3 families), spherocytosis (2 patients), gallstones (4 patients), kidney stones or nephrocalcinosis (2 patients), a vitamin K-responsive bleeding diathesis (2 patients), and height $\geq 90\%$ for age (40% of the patients). Six patients have had biochemical evidence of liver dysfunction, and 2 patients died after significant liver hemorrhage.

Conclusions: These data suggest that the prognosis for X-linked MTM may not be as poor as previously reported. However, at least some long-term survivors appear at risk for medical complications involving other organ systems, and patients should be carefully monitored for these potentially life-threatening complications. The pleiotropic symptoms demonstrated in these patients strongly suggest that the function of the MTM1 protein is not limited to developing muscle cells. (*J Pediatr* 1999;134:206-14)

X-linked myotubular myopathy (McKusick no. 31040) is a congenital myopathy in which affected male subjects typically present with severe hypotonia and respiratory distress at birth. Surviving patients have prolonged ventilator dependence and grossly delayed motor milestones but usually have intact intelligence.¹⁻³ However, the long-term prognosis as reported in the literature is generally poor, and withdrawal of ventilatory support for affected infants is not uncommon. Diagnosis of MTM1 has relied on a positive family history and the demonstration of the presence of characteristic central nuclei resembling fetal myotubes in muscle biopsy specimens from affected male subjects, as well as the exclusion of congenital myotonic dystrophy.⁴ Autosomal forms of MTM have also been described^{1,3} but are reported to have a milder phenotype than the X-linked form.

MTM Myotubular myopathy
MTM1 X-linked myotubular myopathy

In 1990, linkage of MTM1 to Xq28 was established, leading to the isolation of a candidate MTM1 locus in 1996.⁵ The gene encodes a ubiquitously expressed protein named *myotubularin*. Recently, nuclear localization and serine/tyrosine phosphatase activity have been demonstrated for the protein, although its cellular targets and exact function remain to be elucidated.⁶ Mutations in myotubularin have been demonstrated in more than 100 patients worldwide by muta-

From Children's Hospital Research Foundation and Department of Pediatrics, The Ohio State University, Columbus; Department of Pathology and Department of Molecular and Human Genetics, Baylor College of Medicine, Houston, Texas; and Department of Biology, California State University, Northridge.

Supported by Muscular Dystrophy Association and Children's Hospital Research Foundation.

Submitted for publication Aug 7, 1998; revision received Oct 15, 1998; accepted Oct 28, 1998.

Reprint requests: Gail E. Herman, MD, PhD, Associate Professor, Children's Hospital Research Foundation, 700 Children's Dr, Columbus, OH 43205.

Copyright © 1999 by Mosby, Inc.

0022-3476/99/\$8.00 + 0 9/21/95474

tion scanning and/or direct genomic sequencing.⁷⁻¹¹ However, no mutations have been identified in approximately 20% of male subjects with presumed X-linked MTM (G. Herman and European MTM Consortium. Unpublished results). It is unclear whether these patients represent as-yet unrecognized mutations within the MTM1 locus itself, mutations in another X-linked gene, or autosomal forms of MTM.

As part of our efforts to identify mutations in the MTM1 gene, we gathered clinical records from 49 independent North American families with MTM1.

METHODS

Patients with MTM1 were referred to G.E.H. or A.M. by their physician or by the X-linked Myotubular Myopathy Resource Group, a family support group (see web site, <http://members.aol.com.xmtm/homepage.htm>). For all families, the diagnosis was confirmed by muscle biopsy in one or more affected male subjects. Mutation detection for 26 of the patients by direct genomic sequencing of all 15 exons of the MTM1 gene with intronic primers has been reported.⁷ Mutation analyses for the remainder of the patients were performed as described⁷ and will be reported elsewhere. A detailed questionnaire was mailed to all families. Medical records were obtained; and follow-up telephone interviews with parents, other relatives, and/or physicians were conducted by G.E.H. with informed patient or parental consent. Birth data for patients 11 and 22 have been reported.²

Sections of the formalin-fixed, paraffin-embedded liver biopsy specimens and autopsy samples were examined with hematoxylin-eosin, trichrome, reticulin, periodic acid-Schiff, Perls stain for iron, and rhodanine stain for copper. Immunostaining for vascular endothelium with antibodies to factor 8 (Dako polyclonal) and QB end (Serotec QB

Table I. Features at birth

Finding	No. of patients*	
Prematurity (<36 wk)	10/42 [†]	(24%)
Polyhydramnios	14/31	(45%)
Decreased fetal movement	21/36	(58%)
C-section	19/42	(45%)
Apgar score at 1 min <5	35/39	(90%)
Apgar score at 5 min <5	19/39	(49%)
Weight ≥90th percentile	5/44	(11%)
Length ≥90th percentile	25/36	(69%)
Head circumference ≥90% ile	14/23	(61%)
Hypotonia	45/45	(100%)
Areflexia	18/29	(62%)
Cryptorchidism (bilateral)	17/30	(57%) [‡]
Contractures including clubfeet	8/27	(30%)
Long fingers/toes	9/21	(43%)
Intubation at birth	33/41	(80%) [§]

*The number of patients with the feature/number of patients for whom information was provided about that feature. Percents are given in parentheses.
[†]Excludes 2 sets of twins delivered at 31 and 33 weeks' gestation.
[‡]Three additional patients had unilateral cryptorchidism.
[§]Three additional patients required intubation on day 2 of life.

end-10) was performed with antigen retrieval and secondary Vector ABC kits (Vector Laboratories).

RESULTS

Clinical Findings at Birth

Records from birth were available for 45 of the patients (82%), and their clinical features are summarized in Table I. These data are consistent with neonatal findings previously reported in 8 and 37 additional patients.^{2,5} Eight of our 55 patients died during their initial hospitalization at birth, 40 were discharged home, one remains hospitalized and ventilator-dependent at age 11 months, and the status of 6 patients is not known. Nineteen of the patients were discharged without mechanical ventilation, including 5 patients for whom ventilatory support was withdrawn with parental consent with the presumption that the disorder was progressive and fatal. Eight of the surviving patients who were not receiving ventilatory support subsequently became chronically ventilator-dependent.

The average length of hospitalization at birth for surviving patients was 90 days (range, 6 days to 10 months), excluding patient 20 who was hospitalized for the first 6½ years of his life.

Several patients demonstrated other complications during their initial hospitalization. Four male subjects from 3 families had pyloric stenosis requiring surgical intervention. One patient had tetralogy of Fallot and hypertrophic cardiomyopathy in addition to his MTM1. One patient had a Dandy-Walker malformation, and another had progressive communicating hydrocephalus. Both required ventriculoperitoneal shunts. An association of MTM1 and hydrocephalus has been reported.²

Clinical Findings in Patients with MTM1 Over 1 Year of Age

Thirty-five patients (64%) have survived to at least 1 year of age, and clinical information for 34 of the patients is summarized in Table II; 26 of these male subjects are living. Eight are deceased, and causes of death include 4

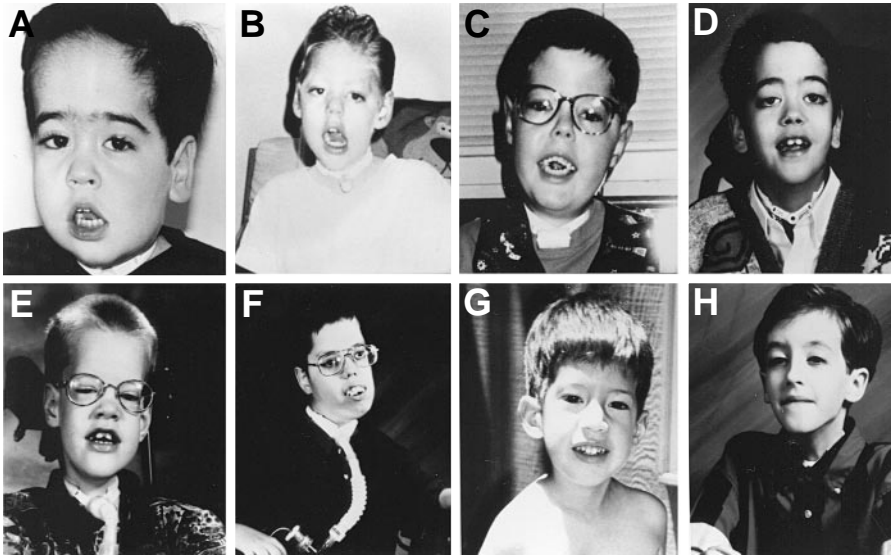

Fig 1. Photographs of 8 boys with MTM1. The patients (see Table II) with their ages are as follows: **A**, patient 12, age 25 months; **B**, patient 10, age 3½ years; **C**, patient 11, age 4½ years; **D**, patient 21, age 5½ years; **E**, patient 32, age 7 years; **F**, patient 18, age 11 years; **G**, patient 14, age 33 months; **H**, patient 4, age 9½ years.

respiratory tract infections or ventilator-related accidents and 2 cases of liver hemorrhage (see below). One patient (no. 9) died during a varicella infection, and patient 28 died at home with no autopsy performed.

As shown in Table II and as discussed below, patients were classified according to phenotype (severe, moderate, or mild). Twenty-one patients, the largest group, demonstrated the classic severe phenotype with characteristic facies, long-term ventilator dependence, and markedly delayed gross motor milestones. Five patients demonstrated the moderate phenotype, based on more rapid attainment of motor milestones and the ability to spend at least 6 to 8 hours per day without ventilatory support when well. Seven patients demonstrated the mild phenotype, based on only slightly delayed motor milestones and the lack of a need for mechanical ventilation beyond the newborn period. Finally, patients 1 and 24, who initially demonstrated the mild phenotype, had a respiratory arrest and severe pneumonia, respectively, and became chronically ventilator-dependent (classification mild to severe).

GROWTH AND GENERAL FEATURES.

Male subjects with the classic severe phenotype have a typical facial appearance. The key features are myopathic facies, dolichocephaly with a high forehead and long face, midface hypoplasia, and a narrow, high-arched palate with malocclusion. Representative photographs of 8 boys ranging in age from 25 months to 11 years are shown in Fig 1. Patients 14 and 4 (panels G and H) have the mild phenotype and demonstrate minimal or no significant facial dysmorphisms.

Despite their chronic illness, linear growth for the majority of the patients remains above the 50th percentile. Fourteen of the patients over 1 year of age (40%) are currently $\geq 90\%$ for height, and an additional 3 patients currently between the 50th and 75th percentiles previously measured $>95\%$. Representative growth curves for 7 patients are shown in Fig 2. Five patients, ranging in age from 3 to 9 years, have documented bone ages >1 standard deviation above their chronologic age in comparison with radiographic standards. Five patients have had premature adrenarche (age range, 5½ to 8 years). Results of endocrinologic tests

including thyroid function tests and determination of levels of growth hormone, insulin growth factor 1, somatomedin C, and adrenal steroids were normal in patients 30 and 32. Bone age determination and endocrinologic testing have not been performed in the other patients. Puberty occurred normally in the 3 patients over 12, and the final adult heights for patients 20 and 26 were within the normal range.

MOTOR AND COGNITIVE DEVELOPMENT.

Gross motor milestones were markedly delayed in all patients with classic X-linked MTM. The average age at which patients with a classic phenotype can sit unsupported is 30 months. None of the patients with classic X-linked MTM are ambulatory. The patients with mild and moderate MTM sat unsupported at an average age of 9.5 months and became ambulatory, in some cases with support, at an average age of 24 months. Muscle strength, for the majority of patients, has slowly improved over time. None of the patients' myopathy has been progressive, a finding that is in contrast with published reports about autosomal forms of MTM.³

Despite their physical limitations, cognitive development in the majority of patients, as measured by formal developmental testing, is normal to advanced for age. Communication for ventilator-dependent patients incorporates speech with capped tracheostomies or passé valves, sign language, and/or communication-assist devices such as writing boards. Several patients over the age of 5 years attend local public schools, usually assisted by a dedicated nurse or aide, and others have homebound teachers to limit their exposure to infectious agents.

Four patients have had a chronic seizure disorder. Three had hypoxic episodes between 6 and 36 months of age after discharge from the hospital without mechanical ventilation, and the fourth had seizures after severe electrolyte disturbances at age 4.

RESPIRATORY STATUS. At present, or at the time of death, of the 35 patients over 1 year of age, 20 are ventilator-dependent 24 hours a day (age range, 1 to 13 years); 7 patients require ventilatory support between 8 and 18 hours per day (age range, 1 to 5 years); and 7 patients are not ventilator-dependent, although they may require administration of oxygen by nasal cannula or mechanical ventilation during respiratory tract infections (age range, 2 to 27 years).

HEMATOLOGIC MANIFESTATIONS. Patients 8 and 11, with identical 4-bp deletions in exon 4, have a mild form of hereditary spherocytosis documented by abnormal osmotic fragility. Patient 11 presented with hemolysis and anemia in association with a respiratory tract infection at approximately 1 year of age. He has an enlarged spleen as demonstrated by abdominal ultrasonography and has intermittent modest hyperbilirubinemia (total bilirubin, 2.0 to 3.0 mg/dL). He has not required transfusions or had other symptoms. Results of osmotic fragility testing of both parents were normal, and there is no family history of spherocytosis or other bleeding disorders. Subsequent to diagnosis of spherocytosis in this patient, an abnormal osmotic fragility test result was obtained for patient 8 who had experienced intermittent mild elevations of liver aminotransferases and hyperbilirubinemia (total bilirubin, 3.0 mg/dL). He also has a negative family history of spherocytosis, demonstrates spherocytes on peripheral smear, and has a mildly elevated reticulocyte count. He is free of symptoms, has normal findings on abdominal sonogram, and has had no further episodes of jaundice. Results of osmotic fragility tests in patients 5 and 31 were normal; none of the other patients have had osmotic fragility testing performed.

GASTROINTESTINAL AND LIVER MANIFESTATIONS. All but 4 of the patients with the mildest forms of MTM (nos.

4, 14, 25, and 26) have required continuous gastrostomy tube feedings, although some of these patients are receiving occasional oral liquids and/or solids. Four patients have had episodes of significant gastrointestinal bleeding that required hospitalization and, in 3 cases, transfusions. These include 3 cases of gastritis and 1 case of duodenal perforation and *Pseudomonas* septicemia after migration of the tip of a gastrostomy tube. Results of antral biopsy and cultures for *Helicobacter pylori* were negative in the one patient for whom they were performed. None of the patients had received oral steroids, although patient 10 had received inhaled steroids before his episode of gastrointestinal bleeding.

Six patients have had documented transient or persistent elevations in serum aminotransferases (aspartate aminotransferase and alanine aminotransferase) suggestive of hepatic dysfunction. Three of the patients presented initially with pruritus. Patient 30

has persistent pruritus with hepatomegaly, although his aminotransferase levels have remained normal. Common infectious causes of liver disease were ruled out in all of the living patients. Serum levels of bile acids, which may be elevated in hepatic pruritus,¹² have not been measured in any of the patients.

Four patients (age range, 18 to 36 months) were found to have gallstones as demonstrated by abdominal ultrasonography. In 3 of the cases the stones were discovered during an evaluation for hepatic dysfunction, and in the fourth case right upper quadrant opacities were noted on a routine chest x-ray film (patient 5). Patient 30 has undergone a cholecystectomy; the other patients remain free of symptoms. Three of the 4 patients have an identical splicing mutation in exon 12, which adds 3 in-frame amino acids to the myotubularin protein. Two of these patients (nos. 29 and 31) have also had a vitamin K-responsive coagulopathy

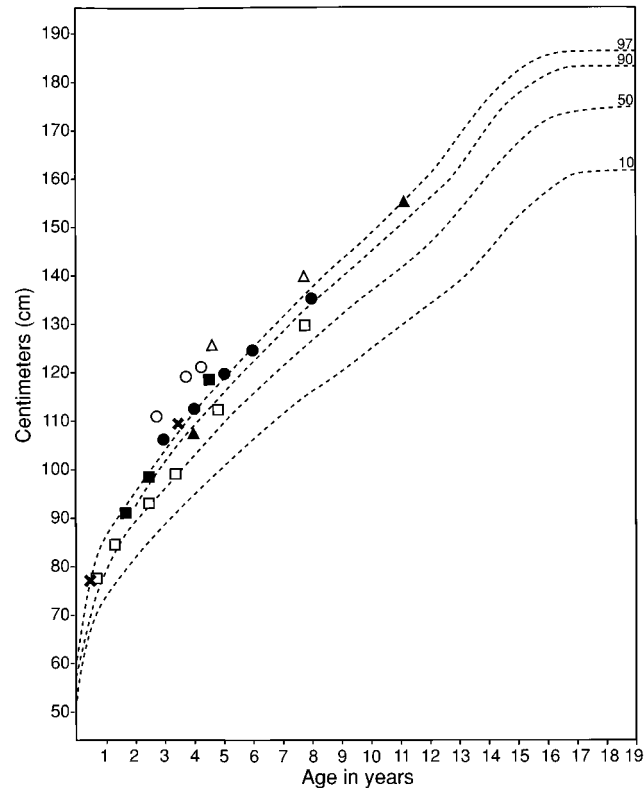


Fig 2. Linear growth charts for 7 patients with MTM1. Shown are patient 6 (■), patient 10 (×), patient 11 (□), patient 18 (▲), patient 19 (○), patient 21 (●), and patient 32 (△).

Table II. Summary of clinical features in patients with MTMI over the age of 1 year

Patient No.	Mutation	Status	Age	Family history	Severity	Height	Cognitive development
1	Deletion of exon 1	Living	7 y	Sib	M/S	NA	Delayed; seizures
2	Sibling of 1	Living	2 y	Sib	Mild	<95%	NI
3	Deletion of exons 1-7	Living	4 y	Sib	S	70%	Delayed
4	Alternate splicing and deletion of exon 2	Living	12 y	Neg	Mild	50%	NI
5	Alternate start codon and frameshift	Living	1 y	U	S	80%	NI
6	Alternate splicing and deletion of exon 4	Living	4 y	U, Sib	Mod	>95%	NI
7	Sibling of 6	Living	3 y	U, Sib	Mod	>95%	NI
8	4-bp deletion and frameshift exon 4	Living	4 y	Neg	S	10%-25%	NI
9	4-bp deletion and frameshift exon 4	Deceased	4 y	Sib	S	NA	NA
10	4-bp deletion and frameshift exon 4	Living	3 y	Neg	S	>97%	Slight delays
11	4-bp deletion and frameshift exon 4	Living	9 y	U	S	50%-75%	NI
12	Nonsense mutation exon 4	Living	5 y	Neg	Mod	80%-90%	NI
13	Missense mutation exon 4	Living	3 y	Neg	Mild	NA	NI
14	Missense mutation exon 4	Living	2 y	U	Mild	50%	NI
15	4-bp deletion and frameshift exon 5	Unknown	3 y	Neg	S	NA	NA
16	Deletion exons 5 and 6	Deceased	5 y	Neg	S	90%-97%	Delayed
17	Deletion exons 6-11	Deceased	5 y	Neg	S	NA	NI
18	Alternate splicing and frameshift exon 7	Living	13 y	Neg	S	95%	NI
19	Alternate splicing and frameshift exon 7	Living	4 y	Neg	S	>97%	NI
20	Missense mutation exon 8	Deceased	20 y	Neg	S	NA	Delayed
21	4-bp deletion and frameshift exon 8	Living	8 y	Neg	S	97%	NI
22	Missense mutation exon 8	Deceased	5 y	Sib	S	NA	NA
23	Missense mutation exon 9	Living	2 y	Neg	S	>95%	Slight delays
24	Missense mutation exon 10	Deceased	22 mo	Neg	M/S	>95%	NI
25	Missense mutation exon 11	Living	2 y	U	Mild	10%-25%	NI
26	Maternal uncle of 25	Living	27 y	+	Mild	"Tall"	NI
27	Missense mutation exon 11	Deceased	4 y	Neg	S	97%	NI; seizures; Dandy-Walker malformation
28	Missense mutation exon 12	Deceased	12 y	Neg	S	NA	Delayed; seizures
29	Alternate splicing and 9 bp insertion exon 12	Living	9 y	Neg	S	NA	NI; seizures
30	Alternate splicing and 9 bp insertion exon 12	Living	3 y	U	S	>95%	NI
31	Alternate splicing and 9 bp insertion exon 12	Living	7 y	Sib	S	75%	NI
32	Nonsense mutation exon 13	Living	7 y	Neg	S	>95%	NI
33	Alternate splicing and frameshift exon 13	Living	1 y	Neg	Mod	>95%	NI
34	Missense mutation exon 14	Living	2 y	Neg	Mod	50%	NI
35	1-bp deletion and frameshift exon 15	Living	3 y	Neg	Mild	>97%	NI

Sib, Affected male sibling; *S*, severe; *NI*, normal; *Neg*, negative; *U*, affected maternal uncle; *Mod*, moderate; *GI*, gastrointestinal; *LFTs*, liver function test results; *VitK*, vitamin K. (See text for explanation of mild, moderate, and severe.) *NA* indicates no information was available or no abnormality was found.

Endocrine	Hematologic	GI/liver	Scoliosis	Ophthalmologic	Renal
NA	NA	NA	+; Spinal fusion	NA	NA
NA	NA	NA	NA	NA	NA
NA	NA	Pyloric stenosis	+; Mild	NA	NA
NA	NA	NA	+; Mild	Ptosis; myopia	NA
NA	NI osmotic fragility	Cholelithiasis (22 mo)	Neg	NI	NA
NA	NA	Pyloric stenosis; GI bleeding/gastritis	Neg	Partial ophthalmoplegia	NA
NA	NA	Duodenal perforation	+; Mild	Partial ophthalmoplegia	NA
NA	Spherocytosis	Mild increase LFTs	Resolved	Myopia; ophthalmoplegia	NA
NA	NA	NI	NA	NA	NA
NA	NA	GI bleeding/gastritis	+	NI	NA
Advanced bone age	Spherocytosis	NA	+	Myopia	NA
NA	NA	Increased LFTs; abnormal hepatic ultrasonographic findings	Neg	Myopia; ptosis	NA
NA	NA	NA	+	NA	NA
NA	NA	NA	Neg	NI	NA
NA	NA	NA	NA	NA	NA
NA	NA	Fatal subcapsular liver hematoma	+	NA	NA
NA	NA	Cholestasis; peliosis hepatis with hemorrhage	+	NA	NA
Adrenarche age 8	NA	NA	+	Myopia	NA
Advanced bone age	NA	Mild increase LFTs	+	Myopia; strabismus	NA
NA	NA	NA	NA	NA	NA
Adrenarche age 6½	NA	NA	NA	Ptosis	NA
NA	NA	NA	NA	NA	NA
NA	NA	Increased LFTs; stomach ulcers/gastritis	NA	NI	Nephrocalcinosis
NA	NA	NA	Neg	NA	NA
NA	NA	NA	Neg	Strabismus	NA
NA	NA	NA	NA	Myopia	NA
NA	NA	Peliosis hepatis	NA	NA	NA
NA	NA	NA	NA	NA	NA
Adrenarche age 7	VitK-dependent coagulopathy	Cholelithiasis	NA	Myopia	NA
Advanced bone age	NA	Hepatomegaly; pruritus; nl LFTs; cholelithiasis (20 mo)	Neg	NA	Hypercalciuria
Advanced bone age	VitK-dependent coagulopathy; NI osmotic fragility	Increased LFTs; cholelithiasis (18 mo)	Neg	Myopia; partial ophthalmoplegia	Nephrolithiasis (uric acid)
Advanced bone age; adrenarche age 5	NA	NA	NA	Myopia; ophthalmoplegia	NA
NA	NA	NA	Neg	NI	NA
NA	NA	NA	Neg	Partial ophthalmoplegia	NA
NA	NA	Pyloric stenosis	+; Mild	NI	NA

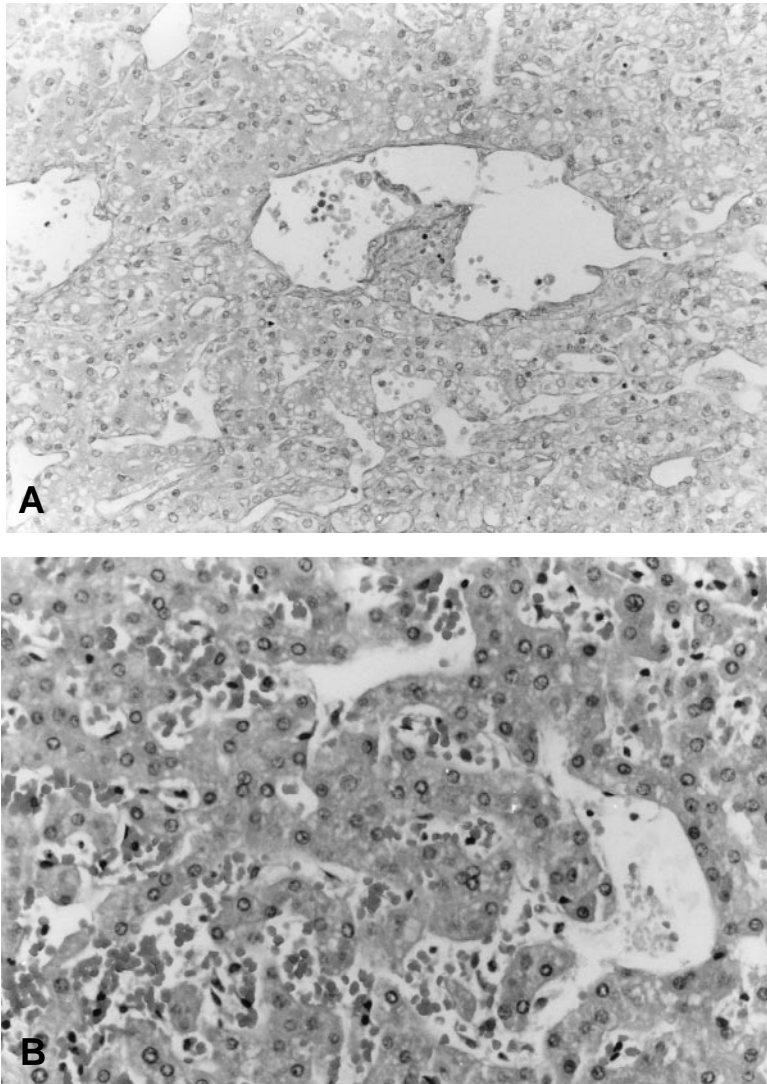


Fig 3. Liver pathology. **A**, Autopsy liver specimen of patient 17 stained with periodic acid-Schiff after diastase reveals highly irregular and focally dilated vascular spaces (original magnification, $\times 160$). **B**, Autopsy liver specimen of patient 27 reveals sinusoidal congestion alternating with scattered dilated channels that are empty (original magnification, $\times 320$). Those spaces generally retained an endothelial lining in which small granular deposits of anti-factor 8 were sometimes present, as in normal sinusoids, and they were likewise focally decorated by anti-QB end (not shown). Some of the hepatocyte cords between the dilated channels are atrophic.

and are receiving long-term vitamin K therapy. Patient 31 presented with significant bleeding after a herniorrhaphy and orchidopexy and had markedly increased protime and partial thromboplastin time, normal levels of factors V and VIII, and markedly decreased levels of factors IX and X, consistent with vitamin K deficiency. Documentation of laboratory testing for the other patient (no. 29) receiving vitamin K is not available; however, he presented

with gastrointestinal bleeding and a prolonged protime.

Two patients (nos. 16 and 17) died after significant hepatic hemorrhage, the latter after a diagnostic open liver biopsy. An autopsy in the first patient revealed acute bilateral lower-lobe pneumonia, a subcapsular hematoma of the liver, and sanguineous ascites, with an estimated loss of 25% of blood volume. No antecedent trauma or cause of the hemorrhage was found. The patient

had no history of liver dysfunction, and no abnormalities were detected in the liver other than the hematoma and congestion. Patient 17 underwent a liver biopsy because of a 6-month history of pruritus and mildly abnormal liver function (γ -glutamyl transferase, 70 U/L [normal, 10 to 22 U/L]; aspartate aminotransferase, 114 U/L [normal, 15 to 50 U/L]; alanine aminotransferase, 35 U/L [normal, 10 to 25 U/L]; total bilirubin, 5.1, direct, 4.3 mg/dL). After the uncomplicated biopsy, hemorrhagic shock developed, and the patient was discovered to have an avulsed subcapsular hematoma. He died 5 days after the operation. The autopsy demonstrated intrahepatic cholestasis with mild acute portal triaditis and bile ductular proliferation. The small size and fragmentation of the biopsy specimen made evaluation of peliosis and large vessel pathology impossible. The liver at autopsy was 20% heavier than expected because of congestion and extensive parenchymal hemorrhage and displayed numerous foci of peliosis (Fig 3, A). Two years earlier, the patient had a hepatic hematoma during a Nissen fundoplication and required a transfusion.

Finally, patient 27, who had a central nervous system malformation and hydrocephalus necessitating ventriculoperitoneal shunting, died at age 4 after a hypoxic episode. He had no known liver dysfunction. At autopsy, he had significant pulmonary inflammation and fibrosis. His liver was 32% heavier than expected because of congestion, and it displayed focal peliosis (Fig 3, B).

RENAL MANIFESTATIONS. One patient each has had calciuria, nephrocalcinosis, or kidney stones. They consisted primarily of uric acid.

SKELETAL MANIFESTATIONS. Several patients have a pectus excavatum deformity. Approximately 60% of the patients have had scoliosis, in some cases requiring bracing or surgery. The scoliosis developed by age 5 in a significant proportion of the cases.

OPHTHALMOLOGIC MANIFESTATIONS.

Partial or complete ophthalmoplegia and ptosis have previously been reported in MTM1^{1,5} and were common, but not universal, in our patients. In addition, 10 patients over the age of 3 (40%) require corrective lenses for myopia, a finding not previously reported.

DISCUSSION

We have presented clinical findings and long-term survival data for 55 patients with X-linked MTM. Mutation analysis was used to confirm the X-linked form of disease. The inclusion of 10 male subjects with mild disease expands the spectrum of the X-linked clinical phenotype. Similar long-term survival with a mild phenotype has also recently been reported in a large X-linked pedigree by Barth and Dubowitz.¹³

Our report has documented several unusual complications in significant numbers of patients with X-linked MTM. Several complications including scoliosis, malocclusion, and myopia may be secondary to the generalized hypotonia; however, additional and unanticipated problems were encountered, which appear unrelated to the primary myopathy. These include a mild form of congenital spherocytosis, rapid linear growth with advanced bone age, premature adrenarche, bleeding diathesis, cholelithiasis, and liver dysfunction. The presence of cholelithiasis in our patients suggests the possibility of occult hemolysis; however, no gallstones have been found in the 2 patients with documented spherocytosis. Several of these complications have been described in patients receiving anabolic steroids, including accelerated growth with advanced bone age, vitamin K-dependent coagulopathies, and peliosis hepatis.¹⁴ In the 2 patients studied, no abnormalities of steroid hormone levels were found, although provocative testing was not performed.

Peliosis hepatis is an unusual vascular lesion characterized by the presence of multiple blood-filled, cystic cavities within the liver or other organs.^{15,16} Its causes are unknown, but it has been associated with chronic wasting disorders, acquired immunodeficiency syndrome, and prolonged use of selected medications including anabolic steroids.¹⁷⁻¹⁹ Although it has been reported as a congenital malformation²⁰ and after asphyxia,²¹ it is extremely rare in the pediatric population. Some peliotic cysts communicate with the hepatic sinusoids and are lined by endothelial cells, whereas others have no endothelial lining.¹⁵ The characteristic cysts can be detected by abdominal ultrasonography²⁰ and magnetic resonance imaging,¹⁹ although they may be misdiagnosed as hemangiomas or other similar masses. In addition to the patients described here, Sarnat et al²² reported a male infant with biopsy-proven MTM who died at 9 months of age from rupture of a spontaneous multifocal hepatic cavernous hemangioma. A patient with mild MTM who died of liver hemorrhage at 9 years of age was found at autopsy to have peliosis hepatis.²³ We have not observed mutations in the MTM1 gene in this patient with a mild myopathy (G. Herman. Unpublished results), which suggests that patients with autosomal forms of MTM may also be at risk for development of peliosis. It is also likely that the abnormal ultrasonographic findings in our patient 12 represent another case of peliosis hepatis. MTM represents the first clear genetic etiology for peliosis; and further studies, perhaps in animal models, may help elucidate the mechanisms involved in the development of this potentially fatal abnormality.

Recent molecular studies aimed at understanding the role of the myotubularin gene in muscle cells suggest that it may function in signaling pathways involved in controlling growth and differentiation. Cui et al⁶ have demonstrated that the MTM1 gene

product has phosphatase enzyme activity and can interact with the "SET" domain (named for the *Drosophila* genes Suvar 3-9, Enhancer-of-zeste, Trithorax) in a diverse group of proteins, for which the exact functions are unknown but which play roles in processes such as chromatin silencing, cell proliferation and differentiation, and oncogenic transformation. Although the exact function of myotubularin remains to be determined, several of the features found in our patients suggest that mutations in the MTM1 gene can be associated with abnormalities of growth and differentiation. They also strongly suggest that the function of myotubularin is not limited to muscle cells but is important in liver, red blood cells, and probably the adrenal cortex, as well as, perhaps, other organs and tissues.

Finally, the data here demonstrate the need for a re-evaluation of genetic and prognostic counseling for patients with X-linked MTM. Although our study suggests that long-term survival is better than previously reported, surviving patients appear at risk for potentially life-threatening medical complications. As molecular studies are performed in greater numbers of patients, they may assist the clinician in predicting which patients may be more likely to have a milder course and which are at risk for medical complications. The true incidence of these complications is difficult to discern because confirmatory laboratory testing has not been performed in most patients. Based on our results, we recommend that all patients with MTM have yearly blood counts, liver function testing, and abdominal ultrasonography. An osmotic fragility test should be performed in any patient with unexplained hemolysis or anemia. Careful examination of clotting parameters should be performed before any surgical procedures. With the recognition that at least 3 patients have had fatal abdominal hemorrhages, possibly because of an underlying defect in hepat-

ic vasculature (peliosis) or coagulopathy, caution in investigating liver dysfunction and performing liver biopsies is advised.

We thank the many clinicians who provided blood samples from and medical records on their patients with MTM1 and Dr A. Feigenbaum, University of Toronto, for providing information about a patient with MTM and peliosis hepatis before publication. We also thank Dr Edith Marley, Sunrise Children's Hospital, Las Vegas, for providing a report and tissue blocks from patient 27; Dr Marcia I. Wills from Johns Hopkins Hospital for histologic slides from patient 16; Dr Shirley Amin, Coral Springs Medical Center, Florida, for biopsy slides from patient 17; and Dr Peter Johnson, Broward General Medical Center, Ft Lauderdale, Florida, for autopsy slides from patient 17. Finally, these studies would not have been possible without the support and help of the numerous families of patients with X-linked MTM, as well as that of the X-linked Myotubular Myopathy Resource Group and Pam, Gary, and John Scoggin.

REFERENCES

- DeAngelis MS, Palmucci L, Leone M, Doriguzzi C. Centronuclear myopathy: clinical, morphological and genetic characters. A review of 288 cases. *J Neurol Sci* 1991;103:2-9.
- Joseph A, Pai S, Holden KR, Herman GE. X-linked myotubular myopathy: clinical observations in ten additional patients. *Am J Med Genet* 1995;59:168-73.
- Wallgren-Pettersson C, Clarke A, Samson F, Fardeau M, Dubowitz V, Moser H, et al. The myotubular myopathies: differential diagnosis of the X-linked recessive, autosomal dominant and autosomal recessive forms and present state of the DNA studies. *J Med Genet* 1995;32:673-9.
- Fardeau M. Congenital myopathies. In: Mastaglia F, Lord Walton J, editors. *Skeletal muscle pathology*. Edinburgh: Churchill Livingstone; 1992.
- Laporte J, Hu LJ, Kretz C, Mandel J-L, Kioschis P, Coy JF, et al. A gene mutated in X-linked myotubular myopathy defines a new putative tyrosine phosphatase family conserved in yeast. *Nature Genet* 1996;13:175-82.
- Cui X, DeVivo I, Slany R, Miyamoto A, Firestein R, Cleary ML. Association of SET domain and myotubularian-related proteins modulates growth control. *Nature Genet* 1998;18:331-7.
- de Gouyon BM, Zhao W, Laporte J, Mandel J-L, Metznerberg A, Herman GE. Characterization of mutations in the myotubularin gene in twenty six patients with X-linked myotubular myopathy. *Hum Molec Genet* 1997;6:1499-504.
- Laporte J, Guiraud-Chaumeil C, Vincent M-C, Mandel J-L, Tanner SM, Liechti-Gallati S, et al. Mutations in the MTM1 gene implicated in X-linked myotubular myopathy. *Hum Molec Genet* 1997;6:1505-11.
- Guiraud-Chaumeil C, Vincent MC, Laporte J, Fardeau M, Samson F, Mandel JL. A mutation in the MTM1 gene invalidates a previous suggestion of nonallelic heterogeneity in X-linked myotubular myopathy. *Am J Hum Genet* 1997;60:1542-4.
- Tanner SM, Laporte J, Guiraud-Chaumeil C, Liechti-Gallati S. Confirmation of prenatal diagnosis results of X-linked recessive myotubular myopathy by mutational screening, and description of three new mutations in the MTM1 gene. *Hum Mutat* 1998; 11:62-8.
- Wallgren-Pettersson C. 58th ENMC Workshop: Myotubular Myopathy; March 20-22, 1998; Naarden, Nederland. *Neuromusc Disord* 1998;8: 521-5.
- Khandelwal M, Malet PF. Pruritis associated with cholestasis, a review of pathogenesis and management. *Dig Dis Sci* 1994;39:1-8.
- Barth PG, Dubowitz V. X-linked myotubular myopathy—a long-term follow-up study. *Eur J Paediatr Neurol* 1998;1:49-56.
- Griffin JE, Wilson JD. Disorders of the testes and the male reproductive trait. In: Wilson JD, Foster DW, Kronenberg HM, Larsen PR, editors. *Williams textbook of endocrinology*. 9th ed. Philadelphia: WB Saunders & Co; 1998. p. 819-75.
- Zafrani ES, Cazier A, Baudelot A-M, Feldmann G. Ultrastructural lesions of the liver in human peliosis: a report of 12 cases. *Amer J Pathol* 1984;349-59.
- Sherlock S, Dooley J. *Diseases of the liver and biliary system*. Boston: Blackwell Scientific Publications; 1993. p. 336.
- Radin DR, Kanel GC. Peliosis hepatis in a patient with human immunodeficiency virus infection. *Am J Radiol* 1991;156:91-2.
- Soe KL, Soe M, Cluud C. Liver pathology associated with the use of anabolic steroids. *Liver* 1992;12:73-9.
- Saatci I, Coskun M, Boyvat F, Cila A, Gürgey A. MR findings in peliosis hepatis. *Pediatr Radiol* 1995;25:31-3.
- Bracero LA, Gambon TB, Evans R, Beneck D. Ultrasonographic findings in a case of congenital peliosis hepatis. *J Ultrasound Med* 1995;14:483-6.
- Selby DM, Stocker JT. Focal peliosis hepatis, a sequela of asphyxial death? *Pediatr Pathol Lab Med* 1995;15: 589-96.
- Sarnat HB, Roth SI, Jimenez JF. Neonatal myotubular myopathy: neuropathy and failure of postnatal maturation of fetal muscle. *Can J Neurol Sci* 1981;8:313-20.
- Herman GE, Feigenbaum A, Zhao W, Finegold M, deGouyon B, Laporte J, et al. Medical complications in long-term survivors with X-linked myotubular myopathy (MTM1) [abstract]. *Am J Hum Genet* 1997;61:A49.